

# Case Report Rapport de cas

## Anaphylactic reaction in a cow due to parenteral administration of penicillin-streptomycin

Arash Omid

**Abstract** – Anaphylactic reaction rarely occurs after the 1st injection of penicillin-streptomycin in cattle. Immediately following intramuscular injection of a Holstein-Friesian cow with penicillin-streptomycin, the cow showed abnormal clinical signs that included respiratory distress, urticaria, and lacrimation. Recovery took approximately 2 h after intramuscular injection of dexamethasone. This report presents clinical findings recorded 20 and 40 h later.

**Résumé** – Réaction anaphylactique chez une vache due à une administration parentérale de pénicilline-streptomycine. Une réaction anaphylactique se produit rarement après la première injection de pénicilline-streptomycine chez le bétail. Immédiatement après une injection intramusculaire chez une vache Holstein-Friesian avec de la pénicilline-streptomycine, la vache a manifesté des signes cliniques anormaux qui incluaient la détresse respiratoire, l'urticaire et la sécrétion de larmes. Le rétablissement a duré environ 2 heures après l'injection intramusculaire de dexaméthasone. Ce rapport présente les résultats cliniques enregistrés 20 et 40 heures plus tard.

(Traduit par Isabelle Vallières)

Can Vet J 2009;50:741–744

In human medicine, severe immediate type I hypersensitivity (anaphylaxis) is a major cause of adverse drug reactions. Antibiotics (particularly penicillin and cephalosporins), narcotic and nonsteroidal anti-inflammatory drugs are the major culprits (1). Anaphylaxis is defined as a “severe allergic reaction that may cause death,” and in human medicine a consensus definition has recently been proposed (2). In veterinary practice, anaphylactic reactions are usually seen after injections of sera or bacterins. These reactions are usually observed during the 2nd or 3rd injection following an initial “sensitizing” dose (3). Immediate-type hypersensitivity reactions to penicillin are rarely reported in veterinary medicine (4), especially after the 1st injection of penicillin in cattle (5), although the incidence of allergic reactions in this setting is unknown (4).

### Case description

A 5-year-old Holstein Friesian cow was given an intramuscular injection of combined penicillin and streptomycin (Penicillin G procaine 3 MIU & Dihydrostreptomycin sulfate eq. to 3 g base; Nasr, Fariman, Iran) to treat a wound in the leg. This cow had



**Figure 1.** Severe facial edema especially around the eyes (facial-conjunctival angioedema) and lacrimation observed within minutes of the intramuscular injection of penicillin-streptomycin.

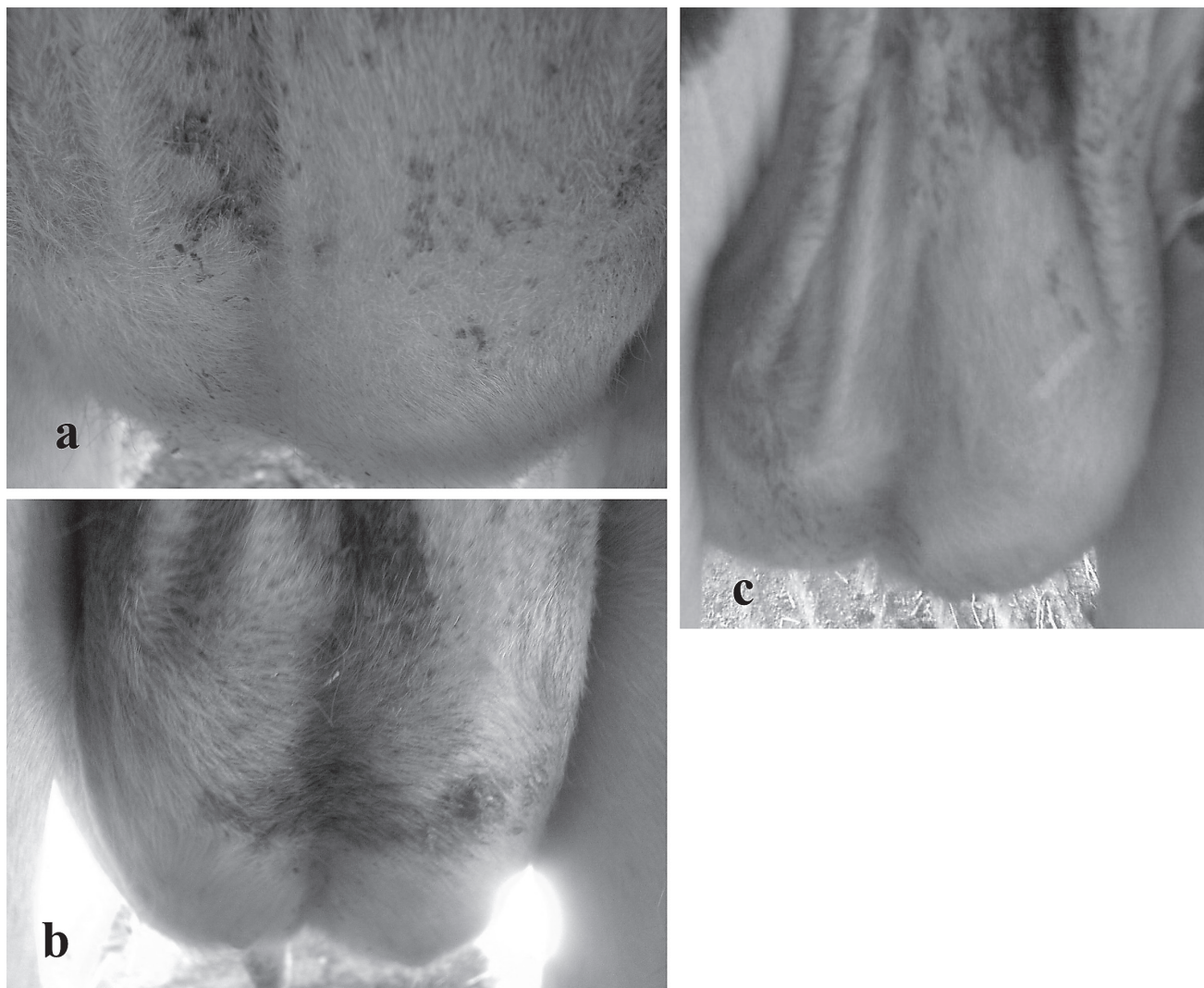
not been treated with either agent previously. Before the injection, clinical findings were normal and were as follows: body temperature of 38.5°C, heart rate of 80 beats per min (bpm), respiratory rate of 20 breaths per min, and ruminal motility rate at 4 contractions per 5 min. Less than a minute following the injection, the cow showed respiratory distress (severe dyspnea), incoordination, anxiety, salivation, urticaria, facial and perineal edema, lacrimation, rhinitis, and shock. Elevation of the body temperature (40°C), heart rate (132 bpm), and respiratory rate (32 breaths per min) was observed and the ruminal motility rate decreased to 1 contraction per 5 min. Edema was observed in

---

Department of Animal Sciences, Faculty of Agriculture, University of Birjand, Birjand, Iran.

Address all correspondence to Dr. Arash Omid; e-mail: arashomidi2@gmail.com

Use of this article is limited to a single copy for personal study. Anyone interested in obtaining reprints should contact the CVMA office (hbroughton@cvma-acmv.org) for additional copies or permission to use this material elsewhere.



**Figure 2.** Urticaria on the caudal surface of the mammary gland; a – immediately after the intramuscular injection of penicillin-streptomycin, b – 20 h after treatment, c – 40 h after treatment. Note the decrease in redness from a to c.

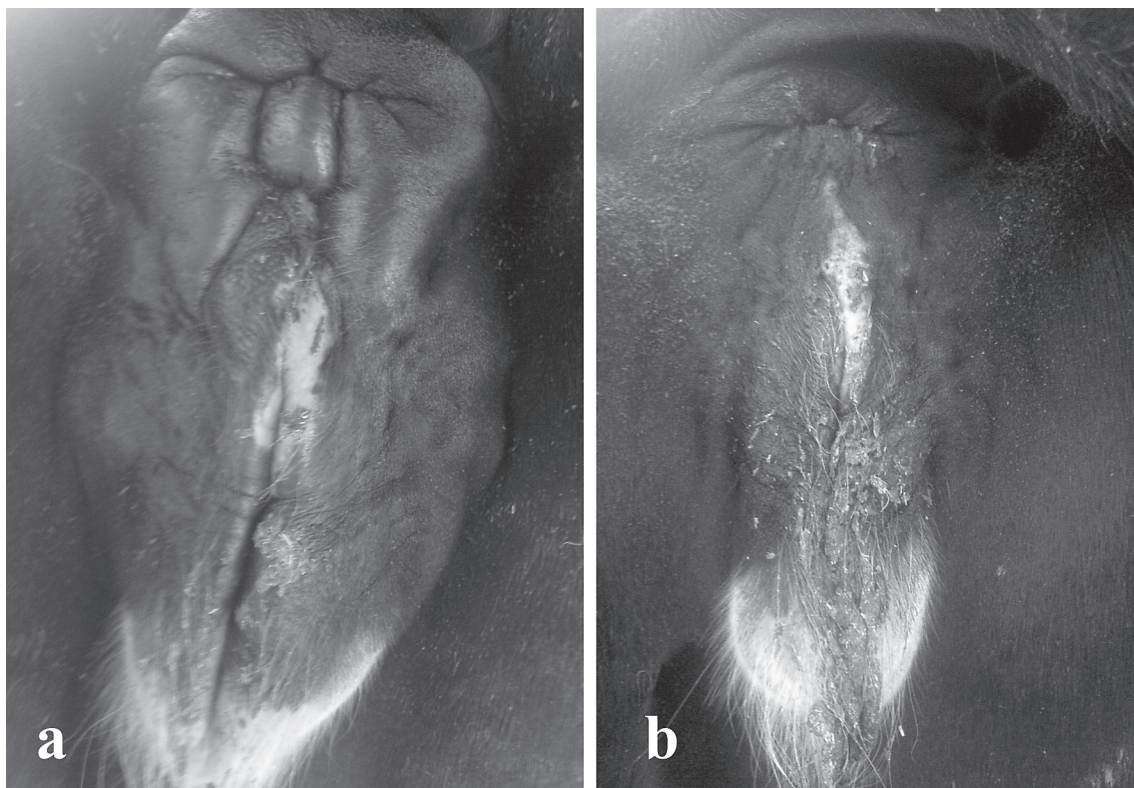the eyelids (Figure 1), lips, face, udder (Figure 2) and external surface of the vulva and anal area (Figure 3). On auscultation of the chest, respirations were wheezy and labored, and rhinitis was observed (Figure 4). This was related to edema and an increase in permeability of pulmonary vessels (5). Epinephrine was not available, so dexamethasone was given intramuscularly (Dexamethasone 0.4%; Nasr), 5 mg/kg body weight (BW). There was marked improvement within 2 h, but redness and urticaria of the mammary gland persisted for 40 h.

### Discussion

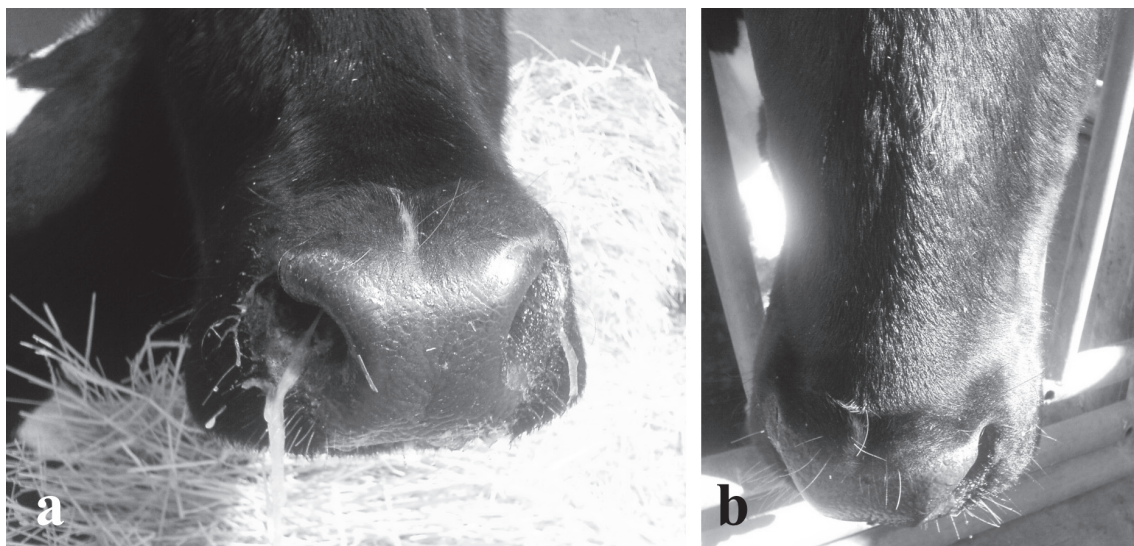
Penicillin has a wide safety margin, and is usually well-tolerated. Penicillin and its metabolites have an affinity for proteins and may form hapten conjugates, which trigger immediate-type hypersensitivity reactions that is mediated by IgE and is directed against various allergenic determinants in the penicillin molecule. In humans, the response usually appears to be directed against a single “major determinant” (benzylpenicilloyl radical), or against certain “minor determinants” (benzylpenicilloic acid and penicillenic acid) (6). Streptomycin is a relatively large

molecule which contains several nitrogen atoms; this may possibly be of significance in the induction of antibody formation (7). Reports of anaphylactic reactions to combined penicillin and streptomycin in humans are fewer than to penicillin and streptomycin separately (8).

Anaphylaxis is a severe multiple organ system immediate-type reaction, affecting the skin, respiratory, cardiovascular, and gastrointestinal systems within minutes to an hour of exposure to a precipitating agent (2). Lethal anaphylaxis is characterized by severe (upper or lower) airway obstruction, and/or shock with profound hypotension. In the absence of cardiovascular monitoring, the observable features of anaphylaxis need to be recognized if appropriate emergency treatment is to be provided. However, it should be noted that in humans, patients may simply suffer a sudden cardiac arrest without any signs of anaphylaxis (9). In cattle, the observed features of anaphylaxis include sudden development of local or diffuse transient subcutaneous edema (angioneurotic edema), affecting the head in most cases, but also the perineum and udder. There is usually diffuse edema of the muzzle, eyelids, conjunctiva, and occasionally the cheeks. This



**Figure 3.** Edema in the anal and external genital area; a – within minutes of the intramuscular injection of penicillin-streptomycin, b – recovery 20 h after treatment.



**Figure 4.** Severe dyspnea and rhinitis; a – immediately after the intramuscular injection with penicillin-streptomycin, b – recovery 20 h after treatment.

is characterized by doughy swelling that pits on pressure; when pressed firmly with the fingertips it retains the indentation for a considerable period of time (10). A rise in temperature ( $40^{\circ}\text{C}$ ) is likely due to muscle tremor (5). Isolated urticaria (mild hypersensitivity), without involvement of other organ systems, may also result from parenteral administration of penicillin (10) or streptomycin (7). Urticarial reactions may appear within minutes, or up to 5 wk after the administration of penicillin (11).

In the latter case (delayed onset), the reactions are probably not IgE-mediated.

Treatment should be administered immediately. A few minutes delay may result in the death of the animal. Most treatment recommendations are based on studies of small animals and humans. Epinephrine administered intramuscularly is often immediately effective (12). However, most anaphylactic reactions are usually of moderate severity and will spontaneously

resolve over minutes or a few hours in otherwise healthy animals and humans (13). Corticosteroids are said to potentiate the effect of epinephrine and may be given immediately following the epinephrine in order to maintain vascular integrity and to decrease permeability of pulmonary vessels, although the evidence for this presumption is minimal (5). In the case presented here, it is more likely that the gradual improvement over several hours reflected the natural recovery rather than the response to therapy.

Studies in cattle have found that antihistamines and 5-hydroxytryptamine antagonists fail to protect cattle in experimental hypersensitivity. Sodium meclofenamate has been more successful in antagonizing experimental anaphylaxis in cattle and horses. Acetylsalicylic acid was more effective than antihistamines or antiserotonin agents in providing symptomatic relief in experimental acute interstitial pneumonia of calves (5). Oxygen can also be given as soon as possible and preferably under positive pressure to combat pulmonary edema (12). It is important to prevent obstruction of the airways.

Anaphylaxis is rare after the first injection of a conventional drug such as penicillin, because the known mechanisms of penicillin hypersensitivity (via IgE) require prior sensitization. With the increasing use of antibiotics as growth promoters, it is possible that some animals may be sensitized by unrecognized exposure to common determinants (for example common determinants between amoxicillin, ampicillin, penicillin, and a variety of cephalosporins (14).

### Acknowledgments

This case report was carried out with support from the University of Birjand. I am grateful to Dr. Simon Brown for technical support and Dr. Wassim Tawbi for critical reading of the manuscript.

CWJ

### References

1. Brown SG. Clinical features and severity grading of anaphylaxis. *J Allergy Clin Immunol* 2004;114:371–376.
2. Sampson HA, Muñoz-Furlong A, Campbell RL, et al. Second symposium on the definition and management of anaphylaxis: Summary Report-Second National Institute of Allergy and Infectious Disease/Food Allergy and Anaphylaxis Network Symposium. *J Allergy Clin Immunol* 2006;117:391–397.
3. Turnquist SE, Bouchard G, Fischer JR. Naturally occurring systemic anaphylactic and anaphylactoid reactions in four groups of pigs injected with commercially available bacterins. *J Vet Diagn Invest* 1993;5:103–105.
4. Olsén L, Ingvast-Larsson C, Broström H, Larsson P, Tjälve H. Clinical signs and etiology of adverse reactions to procaine benzylpenicillin and sodium/potassium benzylpenicillin in horses. *J Vet Pharmacol Thera* 2007;30:201–207.
5. Radostits OM, Gay CC, Hinchcliff KW, Constable PD. *Allergy and anaphylaxis*. In: OM Radostits, ed. *Veterinary Medicine: A Textbook of the Diseases of Cattle, Sheep, Pigs, Goats and Horses*. 10th ed. Oxford, England: Oxford Univ Pr, 2007:69–72.
6. Baldo BA. Diagnosis of allergy to penicillins and cephalosporins: Structural and immunochemical considerations. *Allergy Clin Immunol Int* 2000:206–212.
7. Soderholm B. Hypersensitivity to streptomycin. *Acta Allergol* 1950;3:329–340.
8. Farber JE, Ross J, Stephens G. Antibiotic anaphylaxis. *Calif Med* 1954;81:9–12.
9. Brown SGA, Blackman KE, Stenlake V, Heddle RJ. Insect biting anaphylaxis: Prospective evaluation of treatment with intravenous adrenaline and volume resuscitation. *Emerg Med J* 2004;21:149–154.
10. Kelly WR. *Veterinary Clinical Diagnosis*. 3rd ed. London: Bailliere Tindall, 1984:440.
11. Boonk WJ, van Ketel WG. The role of penicillin in the pathogenesis of chronic urticaria. *Br J Dermatol* 1982;106:183–190.
12. Kirk RW, Bistner SI. *Handbook of Veterinary Procedures and Emergency Treatment*. 3rd ed. Philadelphia: WB Saunders, 1981:155–156.
13. van der Linden PW, Struyvenberg A, Kraaijenhagen RJ, Hack CE, van der Zwan JK. Anaphylactic shock after insect-siting challenge in 138 persons with a previous insect-siting reaction. *Ann Intern Med* 1993;118:161–168.
14. Baldo BA. Penicillins and cephalosporins as allergens-structural aspects of recognition and cross-reactions. *Clin Exp Allergy* 1999;29:744–749.